

Neglected Traumatic Vulvar Hematoma: A Case Report

Nicholas Pratama,¹ Mutiara Riani,^{1,2} Edihan Mardjuki,^{1,2} Budi Darmawan,^{1,2} Ronny^{3,4}

¹Department of Obstetrics and Gynecology, Atma Jaya Education and Research Hospital, Jakarta, Indonesia

²Department of Obstetrics and Gynecology, School of Medicine & Health Sciences, Atma Jaya Catholic University of Indonesia, Jakarta, Indonesia

³Department of Radiology, Atma Jaya Education and Research Hospital, Jakarta, Indonesia

⁴Department of Radiology, School of Medicine & Health Sciences, Atma Jaya Catholic University of Indonesia, Jakarta, Indonesia

Corresponding Author : Nicholas Pratama, Email: nicholaspratama@hotmail.com

Abstract

Introduction: Vulvar hematoma is a rare condition that can arise from many causes. In serious cases, the patient is hemodynamically unstable and requires immediate treatment. Multiple factors from patients and health care providers impact the outcome.

Case Illustration: P0A0 60-year-old woman presented to the outpatient clinic with a painful lump in her vulva for 1 month after trauma and observation in primary care. She had previously consumed anticoagulants for venous insufficiency. Her family's socioeconomic status was relatively poor. She did not have a complete comprehension of her illness. Physical examination revealed left major labia hematoma with a size of 5 x 10 cm, which was confirmed with ultrasonography. Incision and clot evacuation were performed under general anesthesia and showed a good outcome.

Discussion: Vulva is an external part of female genitalia composed of smooth muscle and loose connective tissue with rich vascularization. This organ is prone to hematoma, and there is no consensus published yet. In this patient, the treatment was delayed for 1 month because of a failure to disseminate a clear care plan combined with the patient's low literacy.

Conclusion: Vulvar hematoma is a rare case that can be treated with a conservative, surgical, or embolization approach. Neglected cases can become chronic hematomas that lead to difficulties in diagnosis. A clear care plan should be successfully disseminated to the patient despite many communication challenges to ensure fast and appropriate medical treatment.

Key words: vulvar hematoma, neglected, health comprehension, low health literacy

Hematoma Vulva Traumatik Terbengkalai : Laporan Kasus

Abstrak

Pendahuluan: Hematoma vulva adalah kasus jarang yang dapat timbul karena berbagai macam penyebab. Pada kasus yang berat, pasien dapat mengalami hemodinamik yang tak stabil dan memerlukan tatalaksana secepatnya. Berbagai macam faktor dari pasien dan tenaga kesehatan mempengaruhi hasil pengobatan.

Ilustrasi Kasus: Wanita P0A0 usia 60 tahun datang ke poliklinik dengan benjolan yang menyebabkan nyeri pada vulva 1 bulan pasca trauma yang telah diobservasi di pelayanan primer. Pasien sebelumnya mengkonsumsi antikoagulan untuk insufisiensi vena. Sosioekonomi keluarga pasien relatif rendah. Pemeriksaan fisik menunjukkan hematoma labia mayor berukuran 5 x 10 cm yang dikonfirmasi dengan ultrasonografi. Pada pasien ini dilakukan insisi dan evakuasi gumpalan darah dibawah anestesi umum yang menunjukkan hasil yang baik.

Diskusi: Vulva adalah organ genitalia eksternal wanita yang tersusun atas otot polos dan jaringan ikat longgar yang kaya vaskularisasi. Organ ini rentan mengalami hematoma dan saat ini belum terdapat konsensus. Penanganan pada pasien ini terlambat selama 1 bulan karena rencana penanganan yang tidak tersampaikan kepada pasien yang memiliki literasi kesehatan rendah.

Kesimpulan: Hematoma vulva adalah kasus jarang yang dapat ditangani secara konservatif, pembedahan, maupun embolisasi. Kasus terbengkalai dapat menjadi hematoma kronis yang menyulitkan dalam diagnosis. Rencana penatalaksanaan yang jelas harus diberikan kepada pasien dengan segala kesulitan komunikasi demi tatalaksana yang cepat dan tepat.

Kata kunci: hematoma vulva, terbengkalai, pemahaman kesehatan, literasi kesehatan rendah

Introduction

The vulva is a soft tissue composed of smooth muscles and loose connective tissue supplied by branches of the pudendal artery. This artery could be rupture and blood could pool in the loose connective tissue. Vulvar collections of blood are called vulvar hematomas, which are rare cases with an incidence of 0.8% among all gynecologic emergencies. Vulvar hematoma can arise from trauma to the perineum, insertion of a foreign body, sexual assault, or consensual coitus. Uncontrolled bleeding will cause the hematoma to enlarge which causes perineal pain that can adversely affect mobility. In more serious cases, the patient can be hemodynamically unstable and require urgent fluid resuscitation or blood transfusion. This is an emergency condition that needs to be treated immediately.^{1,2}

Our case discussed a patient with severe cases that do not receive proper treatment which can arise from multiple factors. The patient came to our clinic after 1 month of observation in a primary healthcare facility. The patient did not have a complete comprehension of her illness which was caused either by unclear communication of the therapy planning by providers or misunderstanding of the given recommendations. A patient's understanding of the recommendations from health care providers is essential for effective health care service. Good comprehension and health literacy combined with appropriate treatment and accessibility to medical facilities are factors that influence the patient's outcome.^{3,4} This factor was lacking in our case and we would like to present a case of a neglected traumatic vulvar hematoma because of unclear communication and the patient low health literacy.

Case Illustration

POA0 60-year-old Asian woman presented to

the outpatient clinic with a lump in her vulva and swelling with pain for 1 month. Pain remained after one month of observation in the primary health care facilities. She stumbled into the gutter in front of her house in the evening and her groin collided with the gutter edge. She was able to walk but could not endure the pain. Pain is aggravated by contact in the groin. The patient denied any history of bruising or uncontrolled bleeding. Painful urination, straining when urinating, and a history of urinary retention were also denied. Vaginal bleeding was also denied.

She previously consumed warfarin and cilostazol from a cardiologist for left leg venous insufficiency and was informed to stop the consumption if any bleeding occurred. The patient stopped consuming the drugs because of the risk of bleeding in her groin. She sought health care in primary care and was informed to be observed for a period that was not specified. She refrained from seeking treatment from higher health care facilities because she did not know that it was an emergency case that needed immediate treatment. After the symptoms remained for 1 month, the patient finally came to our hospital for a more comprehensive workup.

The patient has been retired from work for the last 9 years, and her last education was junior high school. Due to economic reasons, she and her husband of 34 years chose not to have children. Despite being past retirement age, her husband, who is 64 years old, is still working. She lives in a high-density area of 28358 people/sqkm, almost twice the city's average population density of 16882 people/sqkm.^{5,6}

On physical examination, her blood pressure was 130/80 mmHg, heart rate was 62 per minute, respiratory rate was 20 per minute, and temperature was 36.7 C. Labial examination revealed a hematoma in the left major labial with an external size of 5 x 10 cm, tender, and without hyperemia, fluctuation, or open wound. Internal vaginal

examination excluded any lump in the vaginal canal, laceration in the vaginal mucosa, and palpable bony structures. The hematoma was localized in the left labia without any protrusion to an adjacent organ. Laboratory test from complete blood count, prothrombin time, and activated partial thromboplastin time showed normal result. Ultrasound revealed a well-defined hypoechoic lesion with septa and heterogeneous content in the subcutaneous tissue of the left labia region, measuring $\pm 5.24 \times 3.68 \times 7.41$ cm. No internal flow is seen in the doppler. These findings are consistent with chronic organizing hematoma. The patient was then diagnosed with a left vulvar hematoma.

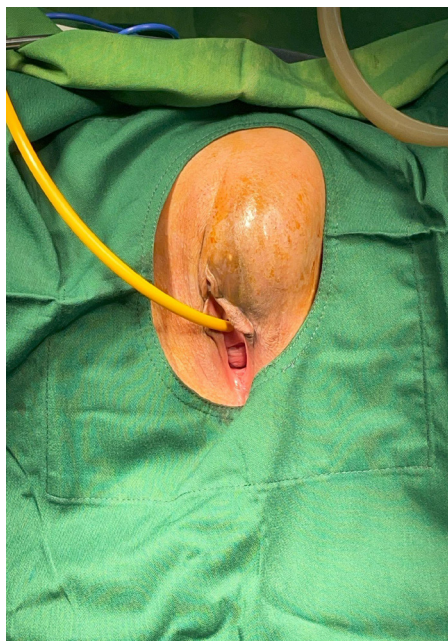


Figure 1 Left Vulvar Hematoma

The patient was hospitalized and planned for surgery. Incision and clot evacuation of the labia was performed in the operating room under general anesthesia. An incision was made in the left major labia with a size of 3 cm. Approximately 50 ml of the liquified blood clot was removed, the cavity was irrigated, and hemostasis was achieved by suturing the bleeding point.

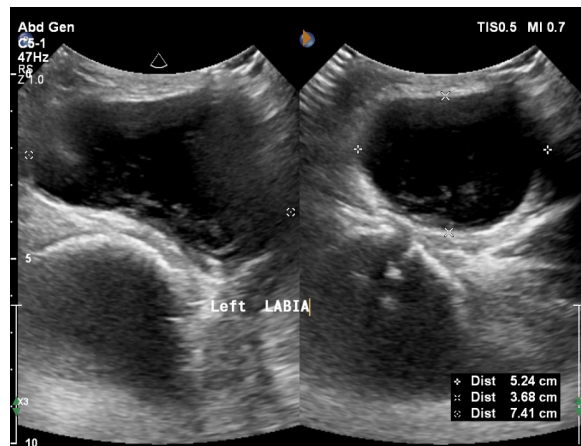

Figure 2 Left Labia Ultrasound

The wound was stitched layer by layer to reduce the risk of dead space. The outer wound was stitched using a simple interrupted technique with a polyglycolic acid suture. The wound was then dressed with framycetin sulfate dressing before being closed with gauze and transparent polyurethane fixation.

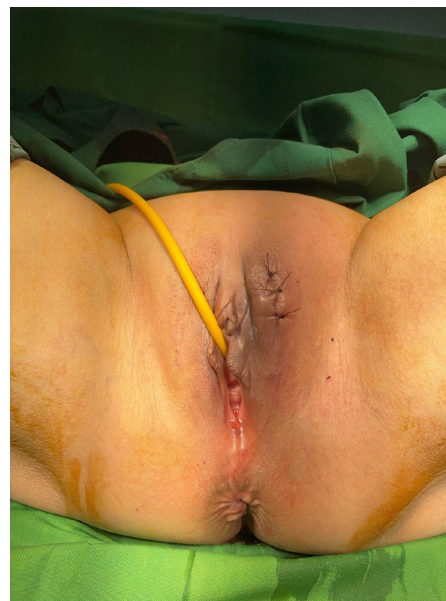

Figure 3 Left Vulvar Hematoma After Surgery

The patient was given prophylactic Ceftriaxone 2g IV before surgery. Symptomatic drugs were prescribed after surgery.

The patient was discharged 2 days

after the surgery and medical treatment was continued for 7 days until the next follow-up. The patient returned to the clinic with the wound closed without any sign of inflammation or rebleeding. The patient could perform normal activities.

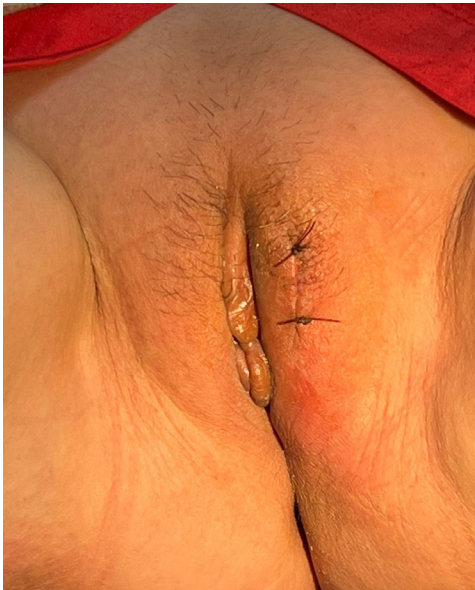

Figure 4 Follow Up on The 10th Day Post-Operative.

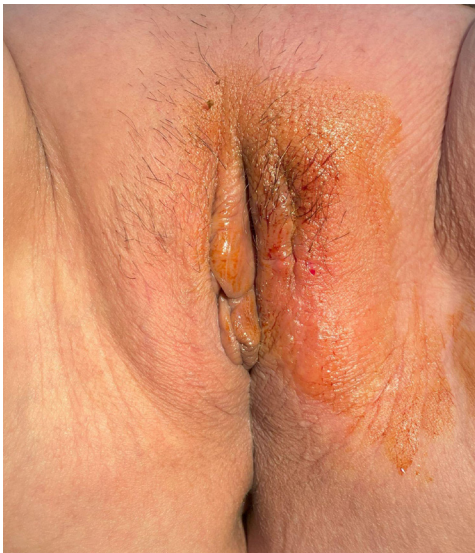

Figure 5 Follow Up on The 17th Day of post-operative

Discussion

The vulva is an external part of the female genitalia that is comprises smooth muscle and loose connective tissue. It is supplied by the pudendal artery that originates from the internal iliac artery and is drained by branches of the internal pudendal vein. This rich blood supply makes the vulva prone to hematoma. Hematoma formation in the vulva is enhanced by the laxity of the superficial perineal fascia. The hematoma can be caused by gynecologic or obstetric causes. Examples of gynecologic causes include trauma, insertion of a foreign body, sexual assault, or consensual intercourse. Of all the gynecologic causes, post-coital injury is the most common. On the other hand, obstetric causes could be episiotomy, vaginal laceration repair, and extensive stretching of the birth canal during vaginal delivery. Spontaneous vessel rupture could be considered if no etiology was found.^{1,2,7}

Warfarin is associated with hemorrhagic events with an estimated 1-year bleeding risk of up to 6.5% affecting soft tissue, gastrointestinal tract, or urinary tract. In severe cases, correction of coagulation disorder using phytonadione and fresh frozen plasma may be needed.⁸ In our case, the hematoma manifested after a direct injury to the groin because of trauma with previous consumption of warfarin.

The treatment of vulvar hematoma is still not clear. The case is rare, and there is no clear consensus published. Patients without severe pain and hematoma expansion can be treated with conservative management with good results but are associated with longer hospital stays and greater subsequent intervention. Diagnosis of acute soft tissue hematoma is usually relatively easy, however in chronic conditions, it is difficult to differentiate between chronic hematoma and soft tissue tumor. Hematomas are reabsorbed, decreasing in size slowly however in rare

cases, they grow in size slowly. A careful search of the 1990–2023 PubMed database yielded no cases of a neglected vulvar hematoma. Research from Negoro et al. showed a chronic hematoma in soft tissue. Chronic hematomas do not show complete absorption and complete liquefaction, they may become cystic and encased in a fibrous capsule that may resemble a malignant fibrous histiocytoma. 5% of malignant fibrous histiocytomas are associated with hematomas.⁹ Conservative treatment by rest, compression, and local cold application is advised. Surgical intervention will be used if the hematoma increases, pain persists or increases and hemodynamic stability is disrupted. Vulvar hematoma more than 4 cm in diameter may cause necrosis because of the pressure it creates and require surgical intervention.¹⁰ In our case, despite the onset of the hematoma a month ago, the pain not subside and the hematoma persisted with a size of 5.2 x 7.4 cm. Surgical intervention by incision and clot evacuation under general anesthesia was decided. A cystic fibrous capsule was not found. Previously, a case in Indonesia also reported an acute vulvar hematoma with etiology of trauma in the vulva with 6.5 cm diameter and onset of 8 h that was managed by incision using local anesthesia and showed a good outcome.¹

If the evacuation of the hematoma, drain, and suture of the bleeding point do not resolve the bleeding, laparotomy to ligate the internal iliac artery can be performed. Arterial embolization is another alternative to the classic surgical approach. Embolization is deemed safe as a minimally invasive method to stop bleeding but is still limited by the availability of interventional radiologists and cath labs.¹¹ The treatment was delayed for 1 month because of unclear communication of the unclear care plan combined with the patient's low health comprehension and literacy of her health. This is an unfortunate case to happen in the capitals of nations

where health care facilities are abundant and access to gynecologists is widely available. Promoting patient comprehension of health care recommendations is integral for effective health care however patients may misunderstand the information. Failure to disseminate complex health issues remains still a challenge for many health care providers. A problem that occurs is that health care provider overestimate patient's level of comprehension and patients are embarrassed to report that they are confused about the information provided.⁴ Knowledge about health and illness is a part of health literacy. Health literacy can be evaluated by how individuals obtain, process, understand their conditions, and make appropriate health decisions. Health literacy is not only rooted in patient education and intelligence but is also influenced by physical, cognitive, and emotional situations. Being ill has a negative influence on the emotional aspect of health literacy which may increase the difficulty for health care providers to explain health issues. Good health literacy is associated with patients being able to engage in disease management and self-care. On the other hand, a patients with poor health literacy have increased hospitalization rates, develop more diseases, less use of preventive care, ineffective health care uses, and ultimately experience higher mortality. Research in Hamburg Germany, developed nation, shows that most of the population still did not know how to identify a health problem as an emergency case. Low health literacy is associated with inadequate health care use and poor outcomes.^{4,12–14}

Social inequalities due to increasing age, low education, low income, employment status, and migration background with non-native language speakers may impact health literacy. The study in Germany reported another example of low health literacy that differs from our case. The writer shows that patients tend to use the emergency services often, although the case is not life threatening.

This leads to additional financial and social burdens on the health care system.^{12,13}

Conclusion

Vulvar hematoma is a rare case with an incidence of 0.8% among all gynecologic emergencies that can be treated with a conservative, surgical, or embolization approach. Neglected cases can become chronic hematomas that lead to difficulties in diagnosis. A clear care plan should be successfully disseminated to the patient despite many communication challenges to ensure fast and appropriate medical treatment. Improvement in providers' communication and intervention by stakeholders to improve general society's socioeconomic status for better health literacy is necessary.

Reference

1. Tjokropawiro BA. Large traumatic vulvar hematoma managed with a simple incision: A case report. *International Journal of Surgery Case Reports*. 2021 Jul;84:106080.
2. Oong GC, Eruo FU. Vulvar Hematoma. In: *StatPearls*. Treasure Island (FL): StatPearls Publishing; 2023
3. Levesque JF, Harris MF, Russell G. Patient-centred access to health care: conceptualising access at the interface of health systems and populations. *Int J Equity Health*. 2013;12(1):18.
4. Kreps GL. Promoting patient comprehension of relevant health information. *Israel Journal of Health Policy Research*. 2018 Sep 18;7(1):56.
5. Badan Pusat Statistik. *Berapa Kepadatan Penduduk DKI Jakarta Saat ini? Unit Pengelola Statistik*. 2020
6. Dinas Komunikasi, Informatika, dan Statistik Provinsi DKI Jakarta. *Data Jumlah Kepadatan Penduduk Per Kelurahan Tahun 2020 - Open Data Jakarta*. 2020
7. Mangwi AA, Ebasone PV, Aroke D, Ngeek LT, Nji AS. Non-obstetric vulva haematomas in a low resource setting: two case reports. *Pan Afr Med J*.
8. Pinheiro NC, Lopes A, Camões A, Monteiro MS. Spontaneous subcutaneous tissue haematoma associated with warfarin. *Case Reports*. 2016 Apr 11;2016:bcr2016215134.
9. Negoro K, Uchida K, Yayama T, Kokubo Y, Baba H. Chronic expanding hematoma of the thigh. *Joint Bone Spine*. 2012 Mar;79(2):192–4.
10. Lapresa Alcalde MV, Hernández Hernández E, Bustillo Alfonso S, Doyague Sánchez MJ. Non-obstetric traumatic vulvar hematoma: Conservative or surgical approach? A case report. *Case Rep Womens Health*. 2019 Mar 25;22:e00109.
11. Machado-Linde F, Capel-Alemán A, Sánchez-Ferrer ML, Cascales-Campos P, Pérez-Carrión A, Ortiz-Vera C, et al. Major post-traumatic non-obstetric large haematoma: transarterial embolisation. *European Journal of Obstetrics and Gynecology and Reproductive Biology*. 2011 Jan 1;154(1):118–9.
12. von dem Knesebeck O, Koens S, Schäferl, Strauß A, Klein J. Public Knowledge About Emergency Care—Results of a Population Survey From Germany. *Frontiers in Public Health*. 2022
13. Hickey KT, Creber RMM, Reading M, Sciacca RR, Riga TC, Frulla AP, et al. Low health literacy. *Nurse Pract*. 2018 Aug;43(8):49–55.
14. Svendsen MT, Bak CK, Sørensen K, Pelikan J, Riddersholm SJ, Skals RK, et al. Associations of health literacy with socioeconomic position, health risk behavior, and health status: a large national population-based survey among Danish adults. *BMC Public Health*. 2020 Apr 28;20(1):565.