

## Case Report: Multigravida at 36 Weeks with Imminent Premature Delivery, Hansen's Disease, and Prior Cesarean Section

Arif Sangjaya,<sup>1</sup> Nuswil Bernolian,<sup>1</sup> Rasmawardiana,<sup>2</sup> Rose Mefiana,<sup>3</sup> Atika Akbari<sup>4</sup>

<sup>1</sup>Obstetrics dan Gynecology Department

<sup>2</sup>Dermatology, Venereology and Aesthetic Department

<sup>3</sup>Anesthesiology and Intensive Therapy Department

<sup>4</sup>Pediatric Department Medical Faculty of Sriwijaya University/

Mohammad Hoesin General Hospital Palembang

\*Corresponding: Arif Sangjaya, Email: dr.arifsangjaya@gmail.com

### Abstract

Hansen's disease, or leprosy, is a chronic granulomatous infection caused by the obligate intracellular bacterium *Mycobacterium leprae*. Pregnancy triggers leprosy in 10–25% of women because of immune disturbances, which affect the disease's course. This study reports the case of a 26-year-old pregnant woman who presented with the chief complaint of abdominal cramps with a contraction every 10 min. The patient admitted to experience vaginal discharge since the onset of pregnancy, without itching or odor. She also revealed a history of leprosy since 2020, which manifested as lumps around the ears, face, and legs, along with numbness at the extremities. She started treatment in 2021 with multi-drug therapy (MDT) but self-discontinued at 14 weeks of pregnancy because of nausea and weakness. The management plan includes dexamethasone ( 12 mg ) intramuscularly to enhance fetal lung maturity, nifedipine ( 10 mg ) every 6 h to suppress preterm contractions, and dermatovenereological assessment to address the patient's history of Hansen's disease. A joint conference is planned to discuss and coordinate the management approach. This study underscores the importance of proper management with WHO-recommended multidrug therapy (MDT) comprising rifampicin, dapsone, and clofazimine. Overall, effective management strategies are crucial to prevent permanent nerve, skin, limb, and eye damage in mothers and infants affected by leprosy.

**Key words :** Hansen's disease, preterm labor, diagnosis.

## Laporan Kasus: Multigravida Hamil 36 Minggu dengan Partus Prematurus Imminens, Morbus Hansen, dan Bekas Sectio Cessaria

### Abstrak

Penyakit Hansen, atau lepra, adalah infeksi granulomatosis kronis yang disebabkan oleh bakteri intraselular obligat *Mycobacterium leprae*. Kehamilan memicu kusta pada 10–25% wanita karena adanya gangguan imunitas yang memengaruhi perkembangan penyakit. Studi ini melaporkan kasus seorang wanita hamil berusia 26 tahun yang datang dengan keluhan utama nyeri perut dengan kontraksi setiap 10 menit. Pasien mengakui mengalami keluarnya cairan vagina yang tidak bau maupun disertai gatal sejak awal kehamilan. Pasien memiliki riwayat penyakit Hansen sejak 2020, yang ditandai dengan benjolan di sekitar telinga, wajah, dan kaki, bersama dengan mati rasa di ujung anggota tubuh. Pasien memulai pengobatan pada 2021 dengan multidrug therapy (MDT) tetapi menghentikannya sendiri pada usia kehamilan 14 minggu karena mual dan rasa lemah yang dirasakan. Rencana tatalaksana mencakup pemberian Deksametason 12 mg intramuskular untuk meningkatkan kematangan paru-paru janin, Nifedipin 10 mg setiap 6 jam untuk menekan kontraksi prematur, dan evaluasi dermatovenereologi untuk mengatasi riwayat penyakit Hansen pada pasien. Konferensi bersama direncanakan untuk membahas dan mengkoordinasikan pendekatan pengelolaan. Studi ini menekankan pentingnya pengelolaan yang tepat, dengan MDT yang direkomendasikan oleh WHO yang terdiri dari rifampisin, dapsone, dan clofazimin. Secara keseluruhan, strategi pengelolaan yang efektif sangat penting untuk mencegah kerusakan saraf, kulit, mata, dan anggota tubuh permanen baik pada ibu maupun bayi yang terkena penyakit ini.

**Kata kunci:** Penyakit Hansen, persalinan prematur, diagnosis.

## Introduction

Hansen's disease, also known as leprosy, is a chronic granulomatous infection caused by obligate intracellular *Mycobacterium leprae*. Discovered by Gerhard Armauer Hansen in 1873, Hansen's disease infects mucocutaneous tissues and peripheral nerves, resulting in sensory loss on the skin, with or without skin lesions and deformities during the disease's progression.<sup>1</sup> In Indonesia, Hansen's disease ranks as the third-highest in the world, following India and Brazil.<sup>2</sup> The country reported 127,558 new Hansen's disease cases globally in 2020, with a prevalence of 0.49 cases per 10,000 people and 11,173 new cases.<sup>3</sup> The interplay between Hansen's disease and pregnancy involves immune responses, nutritional changes, and increased cortisol secretion.<sup>4</sup> *Mycobacterium leprae* induces both cellular and humoral immune responses, and its bacterial load tends to increase during pregnancy, especially in the third trimester.<sup>5</sup>

Hansen's disease primarily affects women of reproductive age, with the highest incidence among those aged 20–39 years.<sup>6,7</sup> Its clinical manifestations are dependent on the host's cellular immune response and range from paucibacillary (PB) to multibacillary (MB) types.<sup>8,9</sup> The disease affects peripheral nerves, skin, and mucous membranes and causes deformities in the eyes, bones, and muscles. During pregnancy, Hansen's disease worsens, leading to erythematous lesions, pain, and permanent nerve damage. Complications related to Hansen's disease and pregnancy include low birth weight, Hansen's disease reactions, the progression of Hansen's disease to the lepromatous type, relapse, increased child infections, and other complications.<sup>5,10,11</sup>

The transmission of Hansen's disease from the mother to the fetus through the placenta is still a debated topic. Research by Girdhar et al. reported that the youngest patient

was three weeks old and from Martinique, a small island near the West Indies.<sup>12</sup> Brubaker et al. documented a case of a 2-3-month-old baby with MH and no known family contact history.<sup>13</sup> These cases support the possibility of intrauterine MH infection, as it seems unlikely to be acquired externally given the extended incubation period, which can span years.

This case report presents the case of an expectant mother with imminent preterm labor, a known history of Hansen's disease, and a previous cesarean section. A nuanced and comprehensive approach was needed that considered both obstetric and dermatological factors. Understanding the complex interactions between Morbus Hansen and pregnancy is crucial for devising effective management strategies for pregnant women with a history of Hansen's disease.

## Case Presentation

A 26-year-old Indonesian woman was referred to the General Hospital of Mohammad Hoesin with the dual challenge of preterm labor and a history of Hansen's disease. With a marriage of nine years, the patient has experienced three pregnancies, one of which resulted in preterm birth. Notably, she has had a history of Hansen's disease since two years, undergoing treatment but discontinuing medication because of pregnancy-related side effects. Her current complaints involve abdominal cramps, and she has experienced leucorrhea since pregnancy onset. In the obstetric examination, the fundal height is measured at 3 fingers below the umbilicus, extending longitudinally, with the back on the left side and the lowest part of the head palpable. The uterine contractions occur once every 10 min, lasting for 10 s. In the vaginal examination, the cervix (portio) is soft and posterior, with an effacement of 0%, and there is no cervical dilation (0 cm). The status of the amniotic fluid is yet to be assessed.

On ultrasound examination (Figure 1), the following findings were observed: A single, live fetus is seen in a cephalic presentation. The fetal biometrics included a biparietal diameter (BPD) of 9.05 cm, an abdominal circumference (AC) of 33.46 cm, a head circumference (HC) of 33.28 cm, and a femur length (FL) of 6.88 cm. The estimated fetal weight (EFW) was measured at 3,183 g. The amniotic fluid was reported to be sufficient, with a single deepest pocket (SDP) measuring 5.85 cm. The placenta is located in the posterior corpus, and the cervical length is 3.30 cm.

Dermatological findings included hyperpigmented patches on the face and left thigh, consistent with Hansen’s disease (Figure 2). The laboratory results revealed moderate anemia with a hemoglobin level of 8.7 g/dL, whereas other laboratory findings were within normal ranges. The immunoserology results showed non-reactive findings for HBsAg, syphilis TPHA, and anti- HIV.

The comprehensive multidisciplinary management plan for the patient includes vigilant monitoring of vital signs, induction of lung maturation using dexamethasone, tocolysis administered through 10 mg nifedipine, and iron supplementation. A dermatovenereological assessment will be conducted as part of the comprehensive management plan, along with collaborative conferences designed to tackle the distinctive challenges presented by concurrent obstetric and dermatological conditions, particularly during this pivotal stage of pregnancy.

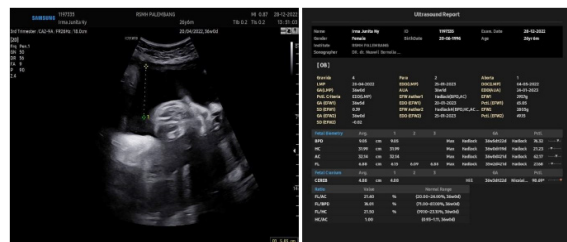

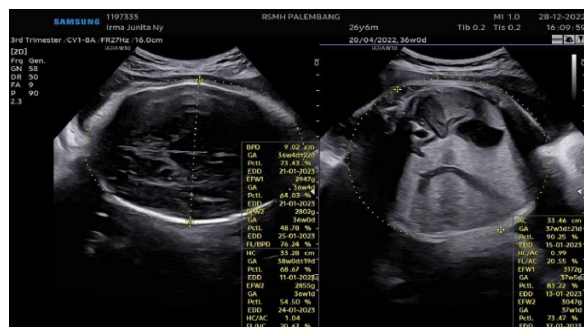
Figure 1 Ultrasonnd Findings

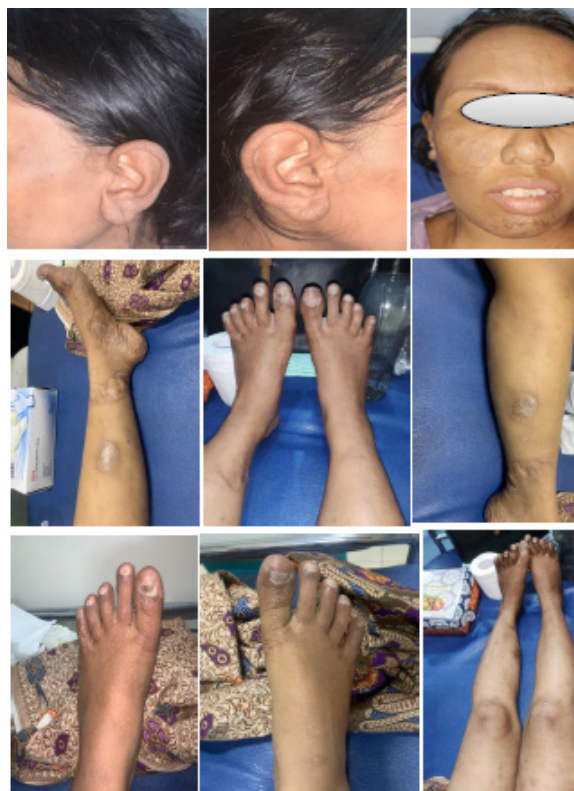

Figure 2 Hyperpigmented Patches Found on Dermatological Examination.

### Discussion

A case of preterm labor and a history of Hansen’s disease in a 26-year-old mother, along with a previous cesarean section, are presented in this report. A total of 6,698 cases of Hansen’s disease in women were reported in Indonesia.<sup>2</sup> Additionally, data from the Dermatology and Infection Polyclinic at the General Hospital of Mohammad Hoesin between 2019 and 2022 revealed 346 cases, with the highest occurrence observed among women aged 26–45years. This report



underlines that pregnancy serves as a triggering factor for leprosy in 10–25% of women due to immune system disturbances.<sup>14</sup> Changes in physiology, hormones, metabolism, and immune responses during pregnancy increase the risk of infection or alter the disease course. Furthermore, the passage mentions that pregnancy with MH can affect the baby through transplacental transmission of *M. leprae*, skin contact, and droplet transmission.<sup>15</sup>

Pregnancy is characterized by a diminished Th1 response, resulting in decreased proinflammatory cytokines, cytotoxic T cells, TNF- $\alpha$ , and IL-12 levels, accompanied by an elevation in anti-inflammatory Th2 cytokines.<sup>4,16,17</sup> This immune shift is influenced by neuroendocrine factors, including increased levels of pregnancy-related proteins such as PZP and glycodelin-A, which inhibit T cell activation.<sup>4</sup> Pregnancy also triggers an enhanced humoral immune response against extracellular pathogens, driven by Th2 lymphocytes stimulating B lymphocytes and promoting antibody production. The mechanism involves a transition from Th1 to Th2 response influenced by elevated estrogen, progesterone, prostaglandin D2, and leukemic inhibitory factor levels during pregnancy. This shift, occurring in the uterine decidua layer, activates B cells while suppressing cytotoxic T cells, thereby suppressing cellular immunity.<sup>4,6</sup> In addition, pregnancy is considered a state of both relative and absolute malnutrition, impacting protein, vitamin, iron, calcium, magnesium, and mineral deficiencies. Malnutrition is linked to disease progression because of its indirect effects on cellular immunity, leading to an increased Th2-mediated immune response, potentially worsening infections and reducing cellular immunity throughout pregnancy.<sup>4,10,18</sup>

Clinical manifestations of Hansen's disease are influenced by bacterial

proliferation, host immune response, and peripheral nerve involvement. The clinical spectrum of the disease, which is related to the host's cellular immunity, consists of paucibacillary (PB) and multibacillary (MB) types. Patients with compromised cellular immunity tend to develop the lepromatous type, while those with intact cellular immunity may experience the tuberculoid indeterminate (I) and borderline (BL) types.<sup>8,9</sup> Hansen's disease becomes more severe during pregnancy, characterized by erythematous lesions, pain, and permanent nerve damage, often affecting the ulnar, median, and peroneal nerves.<sup>6</sup> LL and BL types of the disease during pregnancy are prone to progressing to erythema nodosum leprosum (ENL) due to decreased immunity, but postpartum, a reversal reaction may occur due to immune improvement.<sup>14</sup> Paula et al. reported complications related to Hansen's disease and pregnancy, including low birth weight (<2,000 grams), leprosy reactions, leprosy progressing to the lepromatous type, relapses, increased child infections, and other complications (such as worsening leprosy reactions, exfoliative dermatitis in the fetus, and premature birth) at a rate of 5.5%.<sup>19</sup>

The congenital transmission of Hansen's disease is not well understood; however, transplacental transmission of *Mycobacterium leprae* has been reported in three pregnant armadillos (*Dasypus novemcinctus*). In these cases, *M. leprae* was detected in the decidua tissue and trophoblastic cells of the chorionic villi of the placenta. Transplacental transmission of *M. leprae* stimulates intrauterine immunology.<sup>4</sup> There is minimal evidence of transplacental transmission of *M. leprae* in humans, mostly based on serological findings of IgA (30%) and IgM (50%) antibodies against *M. leprae* detected in the umbilical cord blood of babies born to mothers with lepromatous leprosy (LL). However, these antibodies were not found in babies born to mothers with tuberculoid



MH or healthy controls.<sup>20</sup> Examination of umbilical cord blood and post-delivery blood using IgM and IgG anti-PGL1 tests indicated that the babies were not infected with *M. leprae*, and there was no vertical transmission from the mother to the fetus. The results were seronegative (titer <605 m/mL), umbilical cord blood and amniotic fluid PCR were negative, and histopathology of the umbilical cord and placenta did not reveal acid-fast bacilli (BTA).<sup>17</sup> A case report by Smoot demonstrated the presence of acid-fast bacilli in the lesions of a woman with Hansen's disease at 32 weeks of pregnancy, confirmed by Ziehl–Neelsen staining; however, examination of placental biopsy did not reveal *M. leprae*.<sup>8</sup> Cesarean section delivery was performed on the mother with Hansen's disease, but preventive measures for intrapartum infection are still unknown.<sup>4,7,8</sup>

The role of the placenta in altering the maternal adaptive immune system has been identified.<sup>6</sup> Hansen's disease during pregnancy is infrequently observed, with limited reported cases on its impact on the placenta.<sup>8</sup> Women with leprosy, especially those with LL type, tend to have a lighter placenta and a lower ratio of baby weight to placental weight. The smaller placental size results from a reduction in cell size rather than a decrease in the number of placental cells. Research on 26 pregnant women with MH reported complications, including premature births (22%) and abortions (17%). Intrauterine growth restriction (IUGR) is associated with inadequate fetoplacental function in pregnant women with the MH LL type, characterized by low estrogen secretion at gestational weeks 32–40 compared with the control group. The cause of fetoplacental dysfunction is not fully understood but may be linked to decreased uteroplacental perfusion.<sup>4</sup>

After childbirth, leprosy type 1 reactions occur because of the resurgence of cellular immunity, with type 2 reactions often found

in the third trimester and postpartum. The incidence of infections and infant mortality is higher when the mother is infected with leprosy than infants born to uninfected mothers.<sup>4</sup> Pregnant women with lepromatous leprosy often give birth to infants with low birth weight, premature births, abortions, and IUGR.<sup>6,21</sup> *Mycobacterium leprae* secretion through breast milk, especially in patients with MB type, has been documented. The protective ability of breast milk from MH-infected mothers is comparable. Both breast milks secrete IgA, lactoferrin, albumin, and colostrum. Transmission of Hansen's disease to infants during breastfeeding has been reported before multidrug therapy (MDT) administration and dapsone resistance. Although *M. leprae* has been identified in the breast milk of lepromatous patients without MDT using light microscopy, the viability of *M. leprae* and the oral transmission causing MH remain uncertain.<sup>4,7,14</sup>

Effective management is essential to prevent permanent damage to the nerves, skin, extremities, and eyes in Hansen's disease. The World Health Organization (WHO) recommends Multidrug Therapy (MDT) during pregnancy, comprising rifampicin, dapsone, and clofazimine. MDT administration is considered safe for the fetus, showing no teratogenic effects. Monotherapy with a single agent is not recommended during pregnancy and should be discontinued.<sup>8,9</sup> The duration of MDT varies based on the type, with multibacillary (MB) cases receiving it for twelve months and paucibacillary (PB) cases for six months.<sup>7,22,23</sup> The dosage includes clofazimine 300 mg monthly, then 50 mg daily, rifampicin 600 mg monthly, and dapsone 100 mg daily. Folic acid supplementation at 5 mg is provided during pregnancy because of potential folate absorption reduction caused by dapsone.<sup>7,22</sup> There is no documented increase in the risk of birth defects associated with rifampicin administration during pregnancy. Limited

literature is available on the use of clofazimine during pregnancy and breastfeeding, but no congenital malformations have been observed, and infants were born healthy.<sup>7,9,24</sup> A case study involving a second-trimester pregnant woman with MB-type treated with rifampicin, clofazimine, and dapsone showed no leprosy reactions or neuritis up to 3 months postpartum, with no adverse effects on the baby.<sup>17</sup> MDT is considered safe for pregnant women, breastfeeding mothers, and infants.

WhilesomedrugsinMDT,suchasdapson, may induce anemia and methemoglobinemia in the third trimester, these conditions improve upon discontinuation.<sup>9</sup> Rifampicin and clofazimine can pass through the placenta, and rifampicin may increase the risk of neonatal bleeding. MDT drugs are excreted in breast milk, but no adverse effects on infants, except skin discoloration, have been reported. The use of clofazimine during pregnancy and breastfeeding is limited in the literature, with cases reporting changes in the baby's skin color.<sup>7,9</sup>

A variety of cases demonstrate that continuing MDT into the third trimester and postpartum does not result in adverse effects on the mother or fetus. Regular antenatal check-ups, obstetric scans, and Doppler examinations did not reveal any complications, and routine blood tests during pregnancy were normal.<sup>20,21,25</sup> Other drugs such as ofloxacin and minocycline, which have potential teratogenic effects, should be avoided during pregnancy.<sup>7,9</sup> Separation of the mother and baby, using masks or gowns during breastfeeding, is not recommended. Prophylactic MDT for newborns may be unnecessary because MDT components can pass through placenta and breast milk, and its prophylactic benefits are less significant than those of proper therapy.<sup>26</sup> BCG vaccination is contraindicated during pregnancy and breastfeeding. Antibiotics for ulcer-related infections should be administered on the basis of clinical considerations, considering

local bacterial resistance patterns.<sup>7,22,23</sup> Routine MDT management during pregnancy prevents deterioration, leprosy reactions, and transplacental transmission of *M. leprae* from mother to fetus. Pregnant women with recent MDT or completed MDT within the last 2 years should undergo observation during pregnancy and up to 12 months postpartum, including medical history, physical examination, assessment of nerve function, visual acuity, and assessment of the baby's well-being.<sup>23</sup>

## Conclusion

The prevalence of Hansen's disease in Indonesia and its clinical manifestations during pregnancy, including complications such as low birth weight, pose significant challenges. The potential transmission of Hansen's disease from the mother to the fetus, though not fully understood, raises concerns based on reported cases of early infantile infections. Immunological changes during pregnancy, shifting immune responses, and nutritional alterations, contribute to the complexity of managing Hansen's disease. Multidrug therapy (MDT), involving rifampicin, dapsone, and clofazimine, is deemed safe during pregnancy. Continuation of MDT into the third trimester and postpartum has shown positive outcomes. A multidisciplinary approach is crucial, emphasizing collaboration between obstetric and dermatological care for optimal maternal and fetal outcomes in the presence of Hansen's disease during pregnancy.

## Funding and conflicts of interest

No funding was received for this research. There were no conflicts of interest in conducting this research.

## References

1. Salgado CG, Brito AC de, Salgado UI, Spencer JS. Leprosy. In: Kang S, Amagai M, Bruckner AL, Enk AH, Margolis DJ, McMichael AJ, et al, editor. *Fitzpatrick's Dermatology*. 9<sup>th</sup> edition. New York: McGraw-Hill; 2019. p. 2892–924.
2. World Health Organization. Global leprosy (Hansen disease) Update, 2019: Time to step up prevention initiatives. *Wkly Epidemiol Rec*. 2020;95:417-40.
3. World Health Organization. Leprosy. WHO [Internet]. 2022. [Cited October 1<sup>st</sup> 2022]. Available in: <https://www.who.int/news-room/fact-sheets/detail/leprosy>.
4. Khanna N. Leprosy and pregnancy. In: Kumar B, Kar HK, editor. *IAL Textbook of leprosy*. 2<sup>nd</sup> edition. New Delhi: Jaypee Brothers Medical Publishers(P) Ltd; 2017. p. 352-59.
5. Sekar B. Bacteriology of leprosy. In: Kumar B, Kar HK, editor. *IAL Textbook of leprosy*. 2<sup>nd</sup> edition. New Delhi: Jaypee Brothers Medical Publishers(P) Ltd; 2017. p. 90- 5.
6. Parthasarathy N, Janagond AB, Inamadar AC et al. Dynamic immune status of pregnancy and dermatological diseases: An interplay. *Clin Dermatol Rev*. 2021;5(2):134-35.
7. Butlin CR, Withington S. Mothers and children with leprosy pregnancy and lactation. In: Scollard DM, Gillis TP, editor. *The International Textbook of Leprosy*. New Zealand; p.1-9.
8. Smoot M, Volkmer R, Roth C, Cornelius B. Intrapartum leprosy. *Bayl Univ Med Cent Proc*. 2019;32(3):431–2.
9. Ozturk Z, Tatliparmak A. Leprosy treatment during pregnancy and breastfeeding: A case report and brief review of literature. *Dermatol Ther*. 2017;1-2.
10. Sarkar R, Pradhan S. Leprosy and women. *Int J Womens Dermatol*. 2016(2):117–21.
11. Britton WJ. Leprosy. In: Cohen J, Powderly WG, Opal SM, Calandra T, Gulick RM, Raoult D, editor. *Infectious Diseases*. 4<sup>th</sup> edition. Brighton: Elsevier; 2017. p. 954- 61.
12. Girdhar A, Mishra B, Ravinder K, Lavania, Ashok K. Bagga, dkk. Leprosy in infants two report cases. *Int J Lepr* 1988; 57(2): 472-5.
13. Brubaker ML, Meyers WM, Bourland. Leprosy in children one year of age and under. *Int J Lepr*. 1985; 57(2): 582-8.
14. Lee DJ, Rea TH, Modlin RL. Leprosy. In: Kang S, Amagai M, Bruckner AL, Enk AH, Margolis DJ, McMichael AJ, Orringer JS, editor. *Fitzpatrick's Dermatology*. 8<sup>th</sup> edition. New York: McGraw-Hill; 2018. p. 2258.
15. Adiguna MS. Relaps Morbus Hansen (MH) tipe borderline-lepromatosa tipe borderline (BL) pada seorang wanita hamil. 2018.
16. Robinson DP, Klein SL. Pregnancy and pregnancy-associated hormones alter immune responses and disease pathogenesis. *Horm Behav*. 2012;62(3):263-71.
17. Widasmara D, Basuki S, Florensia D, Setyagraha A. Efektivitas multi drug therapy pada transmisi morbus Hansen transplasental. *Intisari Sains Medis*. 2020;11(2):425-28.
18. Cunningham FG, Leveno KJ, Bloom SL, Dashe JS, Hoffman BL, Casey BM, et al, editor. *Maternal physiology*. In: *Williams Obstetrics*. 25<sup>th</sup> edition. New York: McGraw-Hill; 2018. p. 49–79.
19. Nogueira PSF, Moura ERF, Dias AA, Americo CF, Aguiar LR, Valente Mayenne MQP. Characteristics of pregnant and lactating women with leprosy. *Rev Soc Bras Med Trop*. 2015;48(1):96-8.
20. Chen Z, Kuang YF, Jiang HQ dkk. Intact Mycobacterium leprae isolated from placenta of a pregnant woman, China. *Emerg Infect Dis*. 2019;25(8):1604-7.

21. Bhatia R, Mehta S, Grover A, Dubey s. Leprosy in pregnancy: obstetric diligence is the key. *J Clin Diagn Res.* 2017;11:1-2
22. World Health Organization. Guidelines for the diagnosis, treatment and prevention of leprosy. 2018. p.16-21.
23. Kundakci N, Erdem C. Leprosy: A great imitator. *Clin Dermatol.* 2019.1;37(3):200–12.
24. Upputuri B, Pallapati MS, Tarwater P, Srikantam A. Thalidomide in the treatment of erythema nodosum leprosum (ENL) in an outpatient setting: a five-year retrospective analysis from a leprosy referral centre in India. *PLoS Negl Trop Dis.* 2020;14(10):1-13.
25. Amorim GM, Maestri T, Oppitz A, Leye M, Merini FL, Vignatti LJ. Virchowian leprosy and erythema nodosum leprosum in a 34-week pregnant woman without any previous diagnosis. *Rev Med.* 2022;101(1):1-6.
26. Duncan E. Leprosy in pregnancy. In: Nunzi E, Massone C, editor. *Leprosy.* Milan: Springer. 2012.p.331-40.
- 27.