

## Progressivity of Variable Deceleration to Late Deceleration—A Case Report and It's Implications

Alfonsus Zeus Suryawan, Aditya Rifandi Zaenudin, Febia Erfiandi, Budi Handono

Department of Obstetrics and Gynecology Faculty of Medicine Universitas Padjadjaran/

Dr. Hasan Sadikin General Hospital

Correspondence: Alfonsus Zeus Suryawan, Email: alfonsus21001@mail.unpad.ac.id

### Abstract

**Introduction:** Cardiotocography (CTG) records changes in fetal heart rate and their temporal relationship with uterine contractions. This case report specifically highlights the progression of variable deceleration to late deceleration, its implication, and importance of variable deceleration.

**Case Report:** A 42-year-old G4P2A1 patient at 37–38 weeks of gestation presented to our emergency unit with severe preeclampsia (170/110 mmHg) and irregular heart rate (120 – 70 – 110 bpm). We performed CTG and showed baseline 120–130, with no variability and accompanied by deceleration. The first 2 deceleration occur without the same timing as contraction, and the two later occur after contraction. We performed C-section on the patient and healthy female baby.

**Discussion:** This case provides us with a rather unique pattern of CTG where we could see a slight progression from variable deceleration to late deceleration. Deceleration itself represents a reflex response of the fetus to reduce myocardial workload in response to stress; therefore, it can be secondary to cord compression or other causes. As this condition continues, the fetus deceleration progresses to late deceleration, presenting with a more dire condition and severe acidemic condition.

**Conclusion:** Most of the time variable deceleration are classified as “cord compression” decelerations, while most cases of fetal acidemia in labor are due to reduction in uteroplacental perfusion not the compression of cord. Therefore, variable deceleration is an important sign of fetal acidemia, and when such if present, we should take the initiative for termination of pregnancy to prevent bad outcomes of the fetus.

**Key words :** CTG; variable deceleration; fetal acidemia

## Progresivitas Deselerasi Variabel ke Deselerasi Lambat—Laporan Kasus dan Implikasinya

### Abstrak

**Pendahuluan:** Kardiotokografi merekam perubahan detak jantung janin dan hubungannya dengan kontraksi uterus. Laporan kasus ini hendak menunjukkan perubahan dari deselerasi variabel ke deselerasi lambat serta implikasi dan pentingnya deselerasi variabel.

**Laporan Kasus:** Seorang wanita 42 tahun G4P2A1 gravida 37-38 minggu datang ke IGD dengan preeklamsia berat (170/110 mmHg) dan denyut jantung janin yang irreguler (120 – 70 – 110 x/menit). Setelah dilakukan kardiotokografi didapatkan baseline 120-130, tanpa ada akselerasi dan diikuti deselerasi. Dua deselerasi yang muncul pertama timbul tanpa ada hubungan dengan kontraksi uterus dan dua kontraksi berikutnya terjadi setelah kontraksi. Pasien kemudian dilakukan seksio sesarea dan lahir bayi perempuan sehat.

**Diskusi:** Kasus ini memberikan gambaran kardiotokografi unik dengan adanya progresivitas dari deselerasi variabel ke deselerasi lambat. Deselerasi sendiri merupakan respon fetus terhadap stress dengan menurunkan beban kerja myocardium janin. Hal ini terjadi akibat hipoksia pada janin yang terjadi akibat kompresi tali pusat dan atau penyebab lain. Bila kondisi ini berlanjut menjadi deselerasi lambat maka kondisi fetus akan semakin memburuk dan masuk kedalam asidemia berat.

**Kesimpulan:** Sering kali dalam melihat deselerasi variabel, kita mengklasifikasikannya sebagai deselerasi yang disebabkan penekanan tali pusat/cord-compression yang bila dilakukan resusitasi dapat membaik. Akan tetapi mayoritas kasus dari asidemia fetus pada persalinan terjadi akibat penurunan aliran uteroplacental bukan dari kompresi tali pusat. Oleh karena itu deselerasi variabel justru merupakan tanda penting dalam menilai asidemia fetus dan bila ada dalam pemeriksaan kardiotokografi harus diambil langkah cepat untuk terminasi kehamilan guna mencegah luaran janin yang buruk.

**Kata kunci :** kardiotokografi; deselerasi variabel; asidemia fetus

## Introduction

CTG has been a diagnostic tool for fetal well-being assessment, and records changes in the fetal heart rate and their temporal relationship to uterine contractions.<sup>1</sup> Components of CTG are: baseline rate, baseline variability, accelerations, and decelerations. CTG also has different names depending on how and when they were used, such as admission test for the in-patient, non-stress test to assess biophysical profile if combined with ultrasound examination.<sup>2</sup> Deceleration that occurs during CTG has a lot of meaning depending on when it occurs. Late deceleration appeared as a marked transient bradycardia and was accompanied by a further decrease in fetal oxygen levels.<sup>3</sup> It's a hallmark of fetal acidosis and hypotension. Variable deceleration is presented as abrupt, visually clear decreases in the fetal heart rate without the presence or intervention of uterine contraction. This condition is usually associated with fetal cord compression in early articles.<sup>4</sup> The incidence of fetal acidemia in low-risk pregnancy exponentially increases with the presence of late deceleration. Sameshima et al. stated that the positive predictive value for low pH(<7.1) was exponentially elevated from

0% at no deceleration, 1% in occasional LD, and >50% in recurrent LD with no baseline FHR acceleration and reduced variability.<sup>5</sup> In newer research at Karolinska University Hospital, variable deceleration correlates also with fetal acidemia with confirmation of lactate examination on fetus.<sup>6</sup> The presence of deceleration increases the risk of fetal acidemia 3,2 times.<sup>6</sup> This case report specifically highlights the progression of variable deceleration to late deceleration and its implications.

## Case Report

A 42-year-old G4P2A1 patient at 37–38 weeks of gestation presented to our Emergency Unit with a chief complaint of labor pain 3 h before admission. The patient also presented with high blood pressure (170/110 mmHg) was found during ANC in the midwife in 7 months of gestation. Signs of impending eclampsia, such as severe headache, blurry vision, and epigastric pain, were not observed in this patient. The patient has no history of hypertension in her previous pregnancy. In her previous pregnancies, she had two spontaneous term labors and one spontaneous abortion. She took methyldopa 3 250 mg routinely. Physical examination

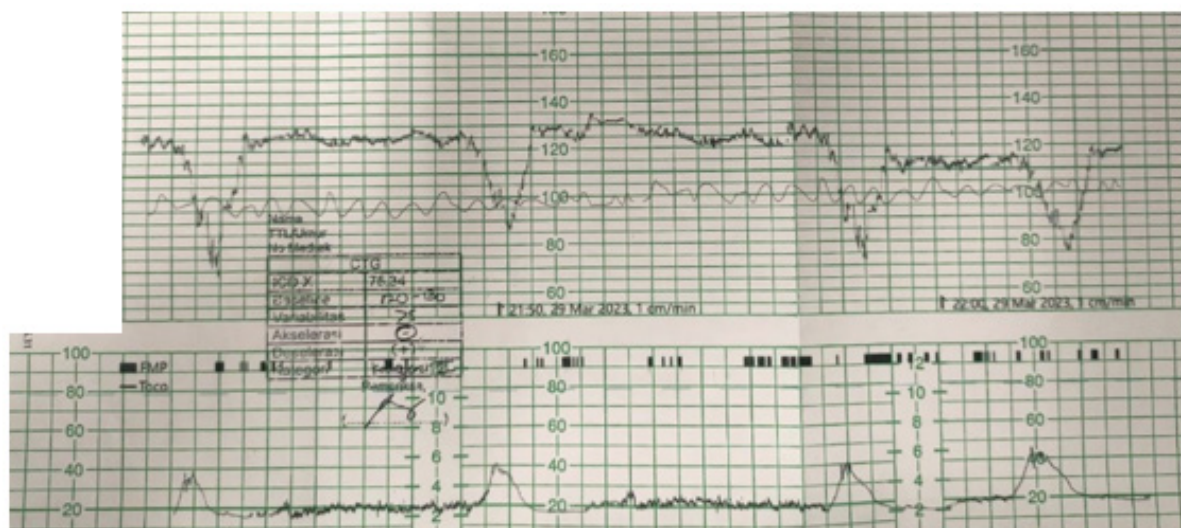
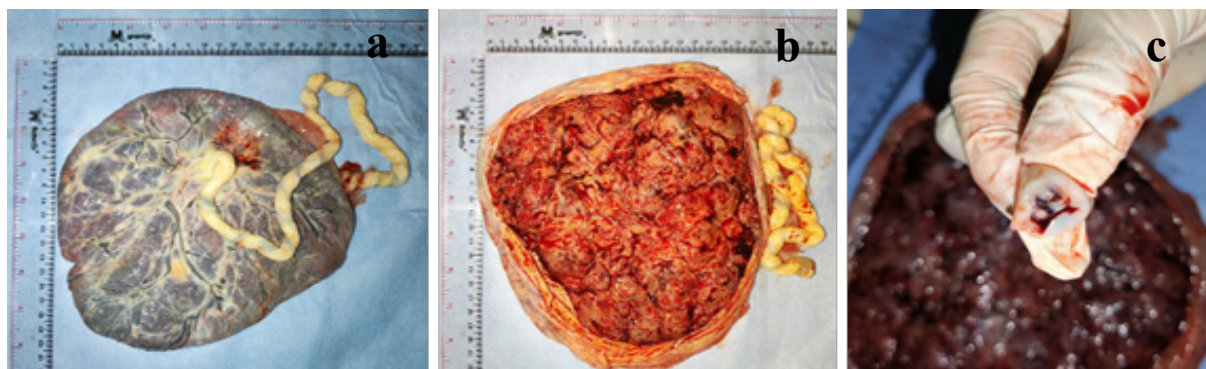

Figure 1 CTG of the Patient 28 March 2023); Highlighted Progression of Deceleration



**Figure 2 Placenta Macroscopy. a. Fetal Side of Placenta; b. Maternal Side of Placenta; c. Umbilical cord artery and vein**

revealed blood pressure 176/101 mmHg, from fetal heart rate found the irregular (120 – 70 – 110 bpm). Her body mass index (BMI) before pregnancy was 22,5 m<sup>2</sup>/kg, which is normal, and she gained 12 kg during this pregnancy. From internal examination, we found that the 2-cm dilation with the cervix was thick and soft, the amnion membrane was still intact, and the head was at station 0.

We performed an admission test with Phillip Avalon in this patient and performed laboratory examinations during the admission test. We found the CTG at baseline 120–130, with variability less than 5 bpm accompanied by deceleration (Fig 1). Deceleration occurs in this case at different times with contraction.

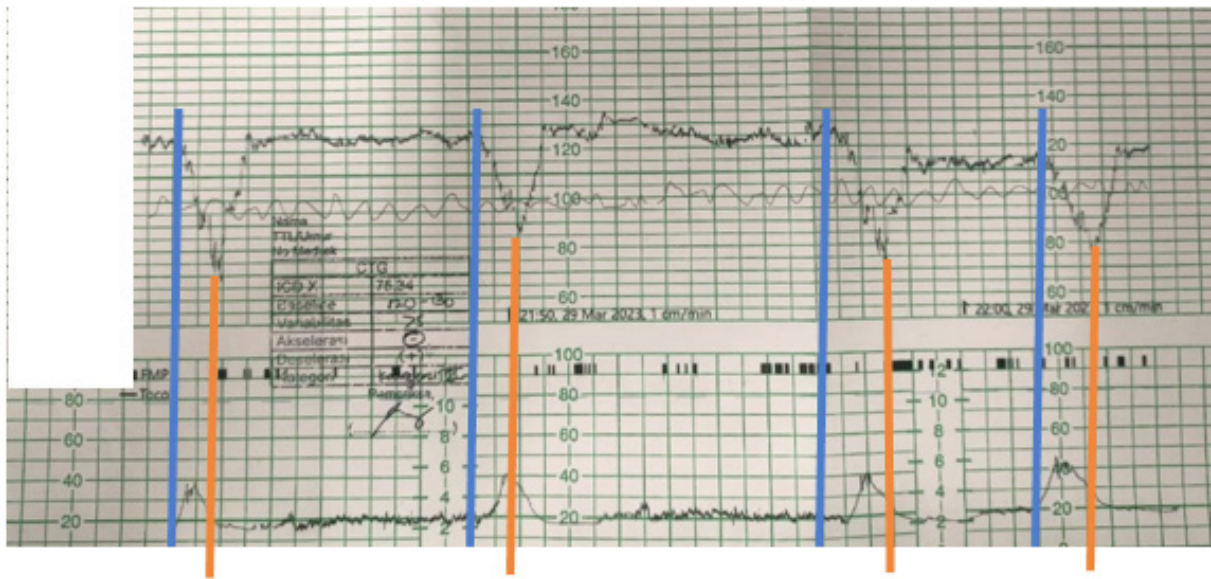
Laboratory results came out after we performed admission test to the patient and we found normal blood results (Hb/Ht/L/Tc : 13.1/36.3/15.9/10/260.000). AST and ALT were within normal limits (16 and 10 U/L), and normal urea and creatinine (7/0,59). The patient had proteinuria (+3). We did not perform fetal lactate examination due to the limitations of our National Health Insurance. We concluded that the patient had G4P2A1 term parturient 1st stage latent phase, severe preeclampsia, and fetal distress. We performed C-section on the patient and healthy female baby weighing 2.730 g with APGAR Score 6–8. The placenta was examined, but we did not perform a pathology examination because of family refusal of placenta examination. We found no

infarction or abnormalities in the umbilical cord (Fig.2). The patient was hospitalized 3 days afterwards and discharged with the baby.

### Discussion

In this peculiar case, the mother presented with several predisposing factors for fetal distress. The patient has severe preeclampsia, which is one of the great obstetric syndromes, and this affects placental circulation greatly.<sup>7</sup> Failure of trophoblast invasion leads to higher pressure in the fetomaternal circulation and later affects the systemic circulation. A 1995 study showed a correlation between severe preeclampsia and these conditions, a lower birth weight, and a higher incidence of SGA, 1-min Apgar scores of 7, and fetal acidosis (pH < 7.2).<sup>8</sup> Acute hypoxia in the fetus occurs due to many factors, which are mainly caused by fetomaternal circulation disturbance and inadequate placentally. This is shown in intrapartum monitoring with CTG. Late deceleration occurs when a decrease in heartrate occurs after the contraction, which would not happen in a normal fetus.<sup>3</sup> This kind of deceleration is latest in which the fetus condition is hypoxic and acidemic.

This case provides us with a rather unique pattern of CTG where we could see a slight progression of variable deceleration to late deceleration (Fig.3). We see the progression from the first two decelerations:



**Figure 3 CTG of the Patient with Detailed Timing of Deceleration. The Line Correlates the Deceleration and Contraction. Blue Line Indicates Onset of Deceleration and Orange Line Indicates Lowest Point (Nadir) of the Deceleration.**

the first one occurs after the contraction and the second one occurs during the contraction. These two deceleration are classified as variable deceleration. Two later deceleration occur after the contractions and are classified as late deceleration. Variable deceleration commonly stated occurs due to umbilical cord compression, causing a transient decrease in fetal heart rate.<sup>4,9</sup> FIGO (2015) also asserted that variable (rapid) deceleration constitute the majority of deceleration during labor and translate a baroreceptor-mediated response to increased arterial pressure, as occurs with umbilical cord compression.<sup>10</sup>

As the result of placental insufficiency of the fetus and aggravated by contraction of the uterus, chronic hypoxia of the fetus occurred in this case presenting as variable deceleration. Deceleration itself represents a reflex response of the fetus to reduce his/her myocardial workload in response to any hypoxic or mechanical stresses; therefore, they can be secondary to cord compression, hypoxemia, head compression, or a combination of these mechanisms.<sup>11</sup> As this condition continues, the fetus deceleration progresses to late deceleration, presenting

with a more dire condition and severe acidic condition. This case also proved variable deceleration was a significant predictor of intrapartum fetal acidemia, as stated also in a research in Karolinska University Hospital by Gyllencreutz et al. (2021). Cumulative 30 min deceleration area >250 beats was found to have a three-fold higher likelihood of intrapartum acidemia.<sup>6</sup> Recent studies have proven that variable deceleration is correlated and caused by uteroplacental deficiency and is an early predictor of fetal hypoxia.<sup>1,6</sup> Somehow, categorization of FHR decelerations can lead to a primary focus on discrimination of majority mistaken variable decelerations to decide which of these “cord compression” decelerations cause fetal asphyxia such as in premature rupture of membrane, while the majority of cases of fetal acidemia in labor are due to reduction in uteroplacental perfusion not the compression of cord.<sup>9</sup> Therefore, variable deceleration is an important sign of fetal acidemia.

### Conclusion

Fetal heart rate monitoring is still useful

in determining fetal wellbeing and is mandatory for cases with maternal morbidity. Deceleration should be considered as an indicator of fetal hypoxia and acidemia, which could be proven with fetal blood sampling. Variable deceleration is not always caused by cord compression, and when such cases present, we should take the initiative for termination of pregnancy to prevent bad outcomes of the fetus.

**Table 1 Timeline of the Patient**

Date	Event
January 2023	The patient was 7 months of pregnancy; diagnosed with preeclampsia
29 March 2023 21.36	The patient was 7 months of pregnancy and diagnosed with preeclampsia Came to Hasan Sadikin Hospital CTG was performed. Progression of variable deceleration to late deceleration was observed. Diagnosed with G4P2A1 term parturient 1st stage active phase of labor; severe preeclampsia; fetal distress
29 March 2023 22.30	C-section was performed. Born healthy female baby weighing 2.730 gram with APGAR Score 6 – 8

**Abbreviations**

CTG : Cardiotocography  
ANC : Antenatal care

**References**

- Alfirevic Z, Devane D, Gyte GM, Cuthbert A. Continuous cardiotocography (CTG) as a form of electronic fetal monitoring (EFM) for fetal assessment during labour. *Cochrane Database Syst Rev.* 2017;2(2):Cd006066.
- Manning FA. The fetal biophysical profile score: current status. *Obstet Gynecol Clin North Am.* 1990;17(1):147-62.

- James LS, Morishima HO, Daniel SS, Bowe ET, Cohen H, Niemann WH. Mechanism of late deceleration of the fetal heart rate. *American Journal of Obstetrics and Gynecology.* 1972;113(5):578-82.
- Hibbard B. Assessment of fetal condition during labour. Hibbard BM, editor *Principles of Obstetrics*, 1st edition. London; UK: Butterworth & Co.; 1988. p. 472-89.
- Sameshima H, Ikenoue T. Predictive value of late decelerations for fetal acidemia in unselective low-risk pregnancies. *Am J Perinatol.* 2005;22(1):19-23.
- Gyllencreutz E, Varli IH, Lindqvist PG, Holzmann M. Variable deceleration features and intrapartum fetal acidemia – The role of deceleration area. *European Journal of Obstetrics & Gynecology and Reproductive Biology.* 2021;267:192-7.
- Brosens I, Pijnenborg R, Vercruyse L, Romero R. The “Great Obstetrical Syndromes” are associated with disorders of deep placentation. *Am J Obstet Gynecol.* 2011;204(3):193-201.
- Yang JM, Wang KG. Relationship between acute fetal distress and maternal-placental-fetal circulations in severe preeclampsia. *Acta Obstet Gynecol Scand.* 1995;74(6):419-24.
- Sholapurkar S. Myths at the core of Intrapartum Cardiotocography Interpretation -Risks of false Ideology, Prospect theory and way forward. *Clinical Obstetrics, Gynecology and Reproductive Medicine.* 2019.
- Ayres-de-Campos D, Spong CY, Chandraran E. FIGO consensus guidelines on intrapartum fetal monitoring: Cardiotocography. *Int J Gynaecol Obstet.* 2015;131(1):13-24.
- Pereira S, Chandraran E. Recognition of chronic hypoxia and pre-existing foetal injury on the cardiotocograph (CTG): Urgent need to think beyond the guidelines. *Porto Biomedical Journal.* 2017;2(4):124-9.