Dandy– Walker Malformation in a Multiparous Woman: A Case Report

Fitra Afdanil,[1] Donel Suhaimi[2]
[1]Resident Department of Obstetrics and Gynecology, Faculty of Medicine, Universitas Riau-Arifin Achmad General Hospital, Indonesia
[2] Department of Obstetrics and Gynecology, Faculty of Medicine, Universitas Riau-Arifin Achmad General Hospital, Indonesia
Coressponding: Fitria Afdanil, Email: fitraafdaniljournal@gmail.com

Abstract
Background: Dandy– Walker malformation (DWM) or syndrome is a posterior fossa anomaly characterized by agenesis or hypoplasia of the vermis and cystic enlargement of the fourth ventricle causing upward displacement of the tentorium and torula. It is characterized by a dilated posterior fossa, cystic enlargement of the fourth ventricle, hypoplasia of the cerebellar vermis, and upward rotation. Most patients have hydrocephalus at the time of diagnosis.
Case presentation: A 36-year-old multiparous woman with 39 weeksof gestation from an obstetrics polyclinic with a plan for induction of labor. During an ultrasound examination, the fetomaternal department found congenital abnormalities in the fetus, namely the presence of hydrocephalus accompanied by Dandy– Walker syndrome. The patient denied the consumption of alcohol or the use of cosmetic drugs such as isotretinoin or blood-thinning drugs. The patient previously had a sudden fever without a reddish rash for 7 days at 6 months of gestation, which healed on its own. The patient admitted to keep a cat at her house since last year. The patient admitted that she had never had her blood checked for TORCH screening. After cervical ripening with misoprostol according to FIGO 25 mcg/PV/6 hours, a live baby girl was born, BW 2440 gr, BL 46 cm, A/S: 6/8.
Conclusions: The patient was admitted to the hospital with the main complaint of G4P3A0L3 Gestational age 39-40 weeks, not in labor, and a live single fetus in the womb. The patient's head presentation from the obstetrics clinic with intermittent episodes of vomiting, headache with plans for induction of labor with ultrasound results of Dandy–Walker syndrome. Pregnant women with DWS in fetal ultrasonic examination should be offered a careful and comprehensive fetal ultrasound scan and further prenatal genetic testing.

Key words: Dandy-Walker malformation, congenital anomaly, pregnancy, prenatal diagnosis

Malformasi Dandy-Walker Pada Wanita Multipara: Laporan Kasus

Abstrak
Latar Belakang: Malformasi atau sindrom Dandy-Walker (DWM) merupakan anomali fosa posterior yang ditandai dengan agenesis atau hipoplasia vermis dan pembesaran kistik ventrikel keempat yang menyebabkan perpindahan tentorium dan torkula ke atas yang ditandai dengan melebarnya fosa posterior, pembesaran kistik ventrikel keempat, hipoplasia vermis serebelar, dan rotasinya ke atas. Kebanyakan pasien menderita hidrosefalus pada saat diagnosis.
Presentasi kasus: Seorang wanita multipara berusia 36 tahun dengan usia kehamilan 39 minggu, pasien dari poliklinik kebidanan dengan rencana induksi persalinan. Pada pemeriksaan USG oleh bagian fetomaternal ditemukan kelainan kongenital pada janin yaitu adanya hidrosefalus disertai Dandy-Walker syndrome. Pasien menyangkal konsumsi alkohol, penggunaan obat-obatan kosmetik seperti isotretinoin atau obat pengencer darah. Pasien sebelumnya mengalami demam mendadak tanpa ruam kemerahan selama 7 hari pada usia kehamilan 6 bulan dan sembuh dengan sendirinya. Pasien mengaku memelihara kucing di rumahnya sejak tahun lalu. Pasien mengaku belum pernah memeriksakan darahnya untuk pemeriksaan TORCH. Setelah pematangan serviks dengan Misoprostol sesuai FIGO 25 mcg/PV/6 jam. Bayi perempuan lahir hidup, BW 2440 gr, BL 46 cm, A/S : 6/8.
Kesimpulan: Pasien masuk RS dengan keluhan utama G4P3A0L3 Usia kehamilan 39-40 minggu, tidak bersalin dan janin hidup tunggal dalam kandungan, presentasi kepala pasien dari klinik kebidanan dengan episode muntah intermiten, sakit kepala dengan rencana induksi persalinan dengan hasil USG Sindrom Dandy-Walker. Keahlian yang cukup diperlukan dalam mendiagnosis dan mengobati malformasi yang disebabkan oleh Dandy Walker. Wanita hamil dengan DWS dalam pemeriksaan USG janin harus ditawarkan pemindaian USG janin yang cermat dan komprehensif serta pengujian genetik prenatal lebih lanjut.

Kata Kunci: Malformasi Dandy-Walker, kelainan kongenital, kehamilan, diagnosis prenatal

Background

Dandy– Walker malformation (DWM) or syndrome is a posterior fossa anomaly characterized by agenesis or hypoplasia of the vermis and cystic enlargement of the fourth ventricle causing upward displacement of the tentorium and torcula.1,2 Most patients have hydrocephalus at the time of diagnosis. DWM is the most common posterior fossa malformation and typically occurs sporadically. It is a rare condition with an estimated incidence of 1 in 10,000–30,000 births. Hydrocephaly, a common finding, is seen in approximately 80% of cases.3 In Indonesia, Dandy-walker case numbers are not known for certain, but hydrocephalus has been found in 50%–60% of treatment visits or procedures neurosurgical operations.4 Many patients remain clinically asymptomatic for years, while others may present with a variety of comorbidities leading to earlier diagnosis. Treatment is generally focused on alleviating hydrocephalus and posterior fossa symptoms, often including surgical interventions such as ventriculoperitoneal and cystoperitoneal shunting.[2,5]

Case Presentation

A 36-year-old multiparous woman with G4P3A0L3 at 39–40weeks of gestational age, not in labor, and intrauterine live singleton fetus, head presentation from an obstetrics polyclinic with intermittent episodes of vomiting, headache, and plan for induction of labor. Complaints of waist pain radiating to the groin denied, bloody mucus denied, unbearable water leakage from the birth canal denied, and bleeding from the birth canal denied. The patient was previously referred from Milano Hospital Teluk Kuantan with the diagnosis of G4P3A0L3 at 33–34 weeks of gestational age, not in labor, hydrocephalus for fetomaternal management. During an ultrasound examination, the fetomaternal department found an enlargement of the ventricle 1.86 cm, cisterna magna wide 3.2 cm, placenta implantation at fundus widely to anterior corpus dous not covering the OUI, maturation grade III, sufficient amniotic fluid with MVP 7.25 cm, with interpretation Intrauterin live singleton fetus, head presentation, gestational age 38-39 weeks according to biometry, ventriculomegaly, and congenital abnormalities in the fetus, namely the presence of hydrocephalus accompanied by Dandy– Walker syndrome. During cardiotocography examination, we found CTG category I with baseline 140 bpm, variability 20 bpm, acceleration positive,

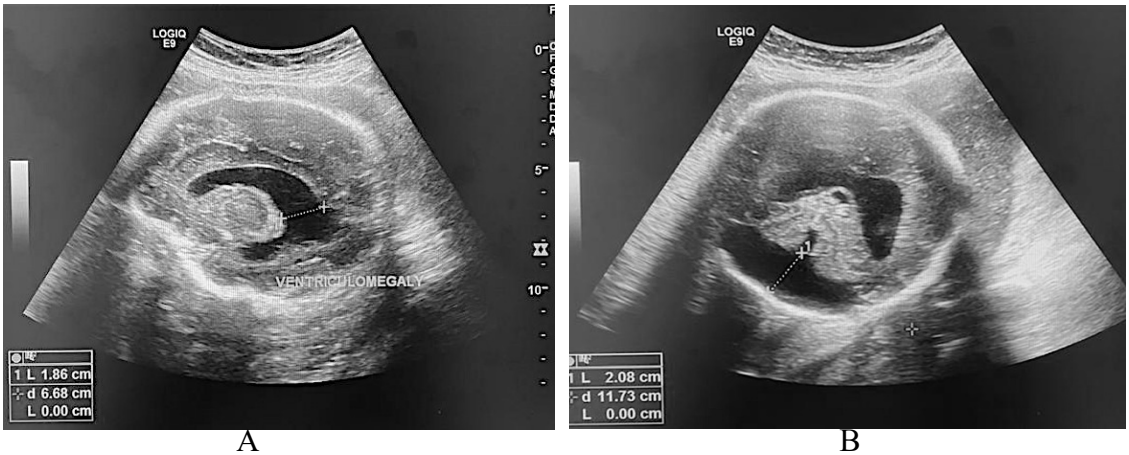

A B

Figure 1 USG examination; A. Ventriculomegaly on Ultrasoundexamination; B. Enlarged 4th ventricle on ultrasoundexamination

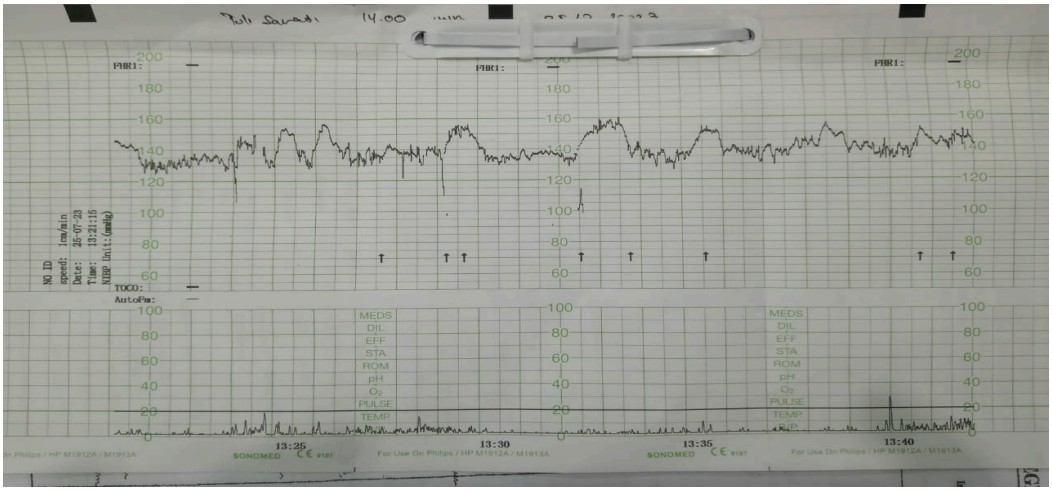

Figure 2 Cardiotocography Examination.



Figure 3 No other Congenital Anomaly was found the Baby

deceleration negative, fetal movements > 2 times in 10 min, and there was contraction. The patient denied the consumption of alcohol or the use of cosmetic drugs such as isotretinoin or blood-thinning drugs. The patient previously had a sudden fever without a reddish rash for 7 days at 6 months of gestation, which healed on its own. The patient admitted to keep a cat at her house since last year. The patient admitted that she had never had her blood checked for TORCH screening. After cervical ripening with misoprostol according to FIGO 25 mcg/PV/6 h, a live baby girl was born, BW 2440 g, BL 46 cm, A/S: 6/8.

Discussion

Historically, DWM was believed to be caused by atresia of the Luschka and Magendie foramina, leading to enlargement of the fourth ventricle and vermian hypoplasia. This disease affects 1–2% of newborns with hydrocephalus.[6] Children with DWS may present at a younger age with hydrocephalus and intellectual disability ranging from mild to severe intellectual impairment and may also show global developmental delays.7 However, recent evidence suggests that DWM results from developmental abnormalities affecting the roof of the rhombencephalon, leading

to variable degrees of vermian hypoplasia and cystic enlargement. Some patients may be asymptomatic with normal intracranial pressure or may have only mild unsteadiness of gait or intellectual impairment until the syndrome is activated by head trauma or a systemic infection. Clinicians can investigate the first symptoms related to the central nervous system, such as hydrocephalus, or diagnose other systemic symptoms, such as cardiac defects, facial defects, limbs, and gastrointestinal or genitourinary system.[8]

This complex malformation may be initiated by two different pathophysiological mechanisms: the arrest of vermian development and failure of the fourth ventricle foramina fenestration, leading to an enlarged Blake's pouch and compression of the vermis. DWM may be isolated or associated with chromosomal abnormalities, Mendelian disorders, syndromic malformations, congenital infections, and various other comorbidities. Central nervous system (CNS) disorders related to DMW include malformations of cortical development, holoprosencephaly, dysgenesis of the corpus callosum, and neural tube defects.[9,10] Rare mutations have been described in some genes, including FOXC1, FGF17, LAMC1, NID1, ZIC1, and ZIC4. The majority of cases are sporadic. However, some may result from chromosomal aneuploidy, Mendelian disorders, and environmental exposures, including congenital rubella and fetal alcohol exposure. Prenatal diagnosis by ultrasound is possible after the 18th week of gestation when the cerebellar vermis has completely developed.11 Diagnosis may be confirmed by magnetic resonanceimaging. For patients with Dandy– Walker variant (DWV), discrepancies may be found in prenatal and postnatal imaging based on the variation of vermian development. Magnetic resonance imaging will also help distinguish DWM from other posterior fossa lesions. Karyotype and postnatal imaging should be offered to all patients with prenatal imaging findings consistent with DWM to confirm findings and search for other possibly associated abnormalities.[11,12] Treatment consists of treating manifestations and associated comorbidities. Most patients present with signs and symptoms of increased intracranial pressure, most commonly related to hydrocephalus and posterior fossa cyst. Therefore, therapy generally controls intracranial pressure, usually through surgery. Pediatric health care providers should be familiar with the broad spectrum of congenital posterior fossa abnormalities to provide an accurate diagnosis, optimal therapy, and genetic counseling

Conclusions

The patient was admitted to the hospital with the main complaint of G4P3A0L3 Gestational age 39-40 weeks, not in labor, a live single fetus in the womb, the patient's head presentation from the obstetrics clinic with intermittent episodes of vomiting, headache with plans for induction of labor with ultrasound results of Dandy–Walker syndrome. Considerable expertise is required to diagnose and treat malformations caused by Dandy-Walker. Health care team members must develop a plan that ensures continuity of care from the early stages of pregnancy, after birth, and throughout childhood. Pregnant women with DWS in fetal ultrasonic examination should be offered a careful and comprehensive fetal ultrasound scan and further prenatal genetic testing.

Source of funding

This research did not receive any specific grant from funding agencies in the public, commercial, or notfor- profit sectors.

Conflict of interest

The author has no conflicts of interest to declare.

Ethical approval

Informed consent was obtained from the patient for the publication of this case report.

Author Contribution

The authors confirm their contribution to the paper as follows: study conception and design: AF, F; data collection: AF; analysis and interpretation of results: AF, F; draft manuscript preparation: AF, F. All authors have reviewed the results and approved the final version of the manuscript.

References

1. Guibaud L, Larroque A, Ville D, Sanlaville D, Till M, Gaucherand P, et al. Prenatal diagnosis of "isolated" Dandy-Walker malformation: Imaging findings and prenatal counselling. Prenat Diagn. 2012;32(2):185–93.
2. Monteagudo A. Dandy-Walker Malformation. Am J Obstet Gynecol. 2020 Dec;223(6):B38–41.
3. Stambolliu E, Ioakeim-Ioannidou M, Kontokostas K, Dakoutrou M, Kousoulis AA. The Most Common Comorbidities in Dandy-Walker Syndrome Patients: A Systematic Review of Case Reports. J Child Neurol. 2017 Sep;32(10):886–902.
4. Mafiana R, Gaus S. Manajemen Neuroanestesi pada Sindrom Dandy Walker dengan Hiperkalemia Neuroanesthesia Management in Dandy Walker Syndrome with Hyperkalemia. Neuroanestesi Indones. 2019;8(2):112–20.
5. Zamora EA, Das JM, Ahmad T. Dandy- walker Malformation [Internet]. StatPearls Publishing. 2023. Available from: https://www.ncbi.nlm.nih.gov/ books/NBK538197/
6. Charan GS, Narang GS, Kaur A, Kaur E. Dandy-Walker Variant Associated with Bilateral Congenital Cataract. Vol. 11, International journal of applied & basic medical research. India; 2021. p. 277–9.
7. Ndu I, Chinawa J, Chikani M, Ibekwe R, Aronu A, Edelu B, et al. Dandy Walker malformation (variant): late presentation with childhood blindness. Niger J Paediatr. 2014;42(1):73.
8. Di Nora A, Costanza G, Pizzo F, Di Mari A, Sapuppo A, Basile A, et al. Dandy-Walker malformation and variants: clinical features and associated anomalies in 28 affected children-a single retrospective study and a review of the literature. Acta Neurol Belg. 2023 Jun;123(3):903–9.
9. Oria MS, Rasib AR, Pirzad AF, Wali Ibrahim Khel F, Ibrahim Khel MI, Wardak FR. A Rare Case of Dandy-Walker Syndrome. Vol. 15, International medical case reports journal. New Zealand; 2022. p. 55–9.
10. Wojcik MH, Agrawal PB. Deciphering congenital anomalies for the next generation. Cold Spring Harb Mol case Stud. 2020 Oct;6(5).
11. Dawra RD, Karia S, Shah N, Desousa A. Psychosis in a Case of Dandy-Walker Syndrome: A Case Report. Vol.11, Journal of clinical and diagnostic research : JCDR. India; 2017. p. VD03–4.
12. Sun Y, Wang T, Zhang N, Zhang P, Li Y. Clinical features and genetic analysis of Dandy-Walker syndrome. BMC Pregnancy Childbirth [Internet]. 2023;23(1):40. Available from: https://=doi.org/10.1186/s12884-023-05367-1